



Center For Advanced Fetal Care Newsletter

Volume 7 Issue 3
Summer of 2016
Tripoli - Lebanon

INSIDE THIS ISSUE

Cord Clamping...	1
Asthma Meds & Birth Defects	1
Types of Imperforate Anus	1
Highlights FMF	2
Highlights Phoenix	2
CFAFC Recommends	3
Abstract Submission SMFM	3
Abstract Submission AIUM	3
ISUOG Pre-Congress	3
Upcoming UCLA Symposium	3
CFAFC News	3
SANA Medical NGO Update	3
Featured Case	4
Featured Quote	4
Upcoming Courses	4

Cord Clamping...

...Instinctive. Intuitive. Impulsive. It is painlessly carried out at birth, yet painfully done all throughout life... We are forced into making painful "cord-clamping" choices in life and many-a-time, we may not be even given the choice and the painful clamp is forced upon us by those whom we value most. Then, we must gather our strength and stamina and take in a hope-infused breath as we move on in life and face yet another **turning point**. From a macro perspective, when our human race is under the threat of further division and earth is under the threat of **global warming**, we must not succumb to asphyxia. We must block the "clamp" by employing our **inventiveness** and **curiosity** in order to properly utilize all **resources** to salvage our humanity and safeguard our planet. We thus dedicate this issue to "cord clamping" and how to combat its after-effects. We present to you the latest publications addressing potential iatrogenic causes of birth defects and how to recognize and classify them sonographically. We present to you highlights from the 15th World Congress of the FMF and the 7th Annual Fetal Cardiology Symposium in Phoenix to further enhance our medical armamentarium. We review for you one of the latest textbooks on fetal imaging. We hope that this issue highlights our unifying **experiences** and future **struggles**, and the pressing need for us to unite and think beyond race, ethnicity and gender. It is only by clamping the cord of segregation and greed that we can ensure our continuity and the **perseverance** of our planet for our children and their children's children.



Antique Stork Scissors 19th Century

Risk of Congenital Birth Defects with Asthma Medications

A recent meta-analysis was carried out by Garne et al to assess the effect of first trimester exposure to asthma medications on congenital birth defects (CBD). The results were published in **BJOG**. The study population consisted of 519242 pregnancies in Norway, Wales and Denmark. Exposure was defined as having an asthma medication prescribed or dispensed 91 days before or after the pregnancy start date. The main outcome measure was the odds ratio (OR) for CBD. The overall exposure rate to asthma medications in the first trimester was 3.76%. This corresponded to an OR for CBD of 1.21 in exposed pregnancies after adjusting for maternal age and socioeconomic status. The most prevalent defect was anal atresia, OR of 3.4, following exposure to inhaled steroids. This was followed by renal dysplasia, OR of 2.37, after exposure to short-acting beta-2 agonists. For severe congenital heart defects, the OR was 1.97 following combined therapy (inhaled steroids and long-acting beta-2 agonists). The authors conclude that their results further support the association between inhaled steroids and anal atresia and may provide new evidence of potential association with combination therapy.



Editor-in-Chief

Reem S. Abu-Rustum, MD
Center For Advanced Fetal Care
rar@cfafc.org

Issue Contributors

Hala Abdallah, MD
halaabdallah2211@gmail.com

Fayez Bitar, MD
drfayezbitar@gmail.com

Ibrahim Ghosn, MD
ibrahim_ghosn@hotmail.com

Sandra Hasbani, MD
sandra_hasbani@gmail.com

Nabil Helou, MD
helounrs@gmail.com

Joan Mastrobattista, MD
mastroba@bcm.edu

Youssef Saaid, MD
youssefsaaid@gmail.com

Mark Sklansky, MD
msklansky@mednet.ucla.edu

Sonographic Determination of Type of Imperforate Anus

Imperforate anus (IA) has always been an elusive prenatal diagnosis. Now comes Lee et al's recent study in **JUM** addressing how to prenatally determine the type of IA using sonography. In their retrospective study of 9499 fetuses, the authors attempted to visualize the sphincter muscles and anal canal mucosa. They classified fetuses as having high- or low-type IA. For the high-type, there had to be no visible sphincter and no visible anal mucosa. For the low-type, there had to be 1 of the following: a small anus, no visible anal mucosa or a close location of the genitalia to the anus with no clear perineal body. Of the 41 prenatally-suspected cases, 32 were confirmed at birth. There were 11 false-negative cases. As such, the overall sensitivity of sonographic prenatal diagnosis for IA was 74%. All the 9 false-positive cases were suspected of having the low-type. The authors conclude that even though it may not always be possible to prenatally diagnose IA, the type may be determined sonographically.

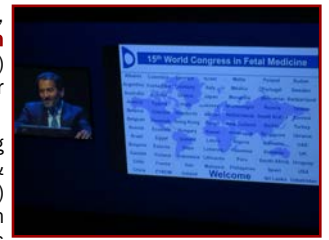

Highlights from the Fetal Medicine Foundation's 15th World Congress Held in Palma de Mallorca, Spain 26 - 30 June 2016. By Youssef Saiid, MD

Who hasn't heard of the beautiful island of Mallorca and its attractive city of Palma? Not only is it a destination for sun, beautiful beaches and fun, but this year it was the locale for the **15th World Congress of the Fetal Medicine Foundation** where over 2200 delegates gathered from 82 countries from all over the world. Professor Roberto Romero (USA) commenced his presentation on 30 years of preterm birth research by stating: "I have been attending this congress for many years and I can confidently say that it is the best fetal medicine congress in the world".

As is customary with Professor Nicolaides, it was another intensely packed 5 days with leading global experts presenting cutting-edge research. The congress started with an outstanding joint session with the International Fetal Medicine & Surgery Society where the most recent advances and research in fetal surgery were discussed. Professor Deprest (Belgium) presented the most recent promising results of the TOTAL trial with a 50% survival rate for fetuses with severe CDH when managed with FETO, versus an 8% survival rate with expectant management. Peiro (USA) discussed the preliminary results of early FETO for extremely severe pulmonary hypoplasia in isolated CDH. The results suggested that early intervention improved survival in severe cases where high mortality is still encountered with standard FETO. In the future, early FETO may be considered as a therapeutic option for all cases with severe forms. The debate was ongoing this year between open versus fetoscopic approach for spina bifida repair with brilliant HD videos presented for both approaches. The fetoscopic approach is demonstrating better later outcomes particularly in terms of the risks of uterine rupture. This year, the relatively new but fast evolving area of fetal cardiac intervention had its fair share. The cardiac session commenced with Professor Simpson (UK), a world expert on fetal and pediatric cardiology, discussing medical intervention for complete heart block and supraventricular tachycardia. He emphasized the importance of involving a fetal cardiologist in the treatment of a fetal arrhythmia. In addition, the FAST trial for atrial flutter and SVT was discussed and more information may be accessed on the **FAST Website**. Dr. Zidere (UK) extensively discussed the prenatal management and postnatal followup of Ebstein's anomaly and tricuspid valve dysplasia. Dr Axt-Flidner (Germany) discussed HLHS management and surgery and outcomes with respect to the different stages of treatment after birth. The prognosis for each stage was presented with a 5-year survival rate as high as 70% if the child survives all the three surgeries. The cardiac session concluded with a series of lectures highlighting the associated risks of growth restriction, placental dysfunction, and brain abnormalities in fetuses with congenital heart disease. Complications of MC twins was another interesting session this year. World experts from Belgium, Bulgaria, Canada, France, Germany, Italy and the UK convened to discuss TTTS, sIUGR and TRAP. They concluded that classification according to UA Doppler in sIUGR is important in determining prognosis, however mode of intervention, whether using laser therapy or cord occlusion, is largely determined by parents' choice and technical difficulty. Monoamniotic twins' management was also discussed but the discussants were still not in agreement on whether inpatient versus outpatient surveillance was best, though all were in agreement to deliver by 32 weeks. The congress also covered other critical topics pertaining to neurosonography and preterm birth. Professor Nicolaides presented his data on preterm birth prevention where there was no difference between the group using a pessary versus controls. Cell free DNA, a topic that dominated last year's congress, was a hot topic, yet again this year. Presentations addressed the various available techniques showing comparative high detection rates for T21. In addition, there was a full day during the congress dedicated to preeclampsia, fetal growth restriction and stillbirth. Professor Nicolaides considers prediction and prevention of preeclampsia as the backbone of pregnancy care. One of his ultimate goals is to improve its detection in order to prevent its complications, namely IUGR and stillbirth. It is anticipated that the ASPREE study results will be available by the end of 2016, making Nicolaides' new approach of screening at 12 weeks (using PAPP-A, PLGF, MAP and UtPI) an essential component of the first trimester scan. There were numerous other sessions as well on growth restriction and its implications on neonates, cardiac remodelling and later diseases in life. Gestational diabetes, gynaecological conditions complicating pregnancy and chronic maternal diseases were also discussed by respective experts in the field.

Last but not least were the unforgettable social events: from the welcome party on Sunday to the dinner party on Tuesday and finally the trip to Valldemossa. These were the perfect opportunities for everyone to relax, connect and mingle after the long intense educational days in a beautiful setting amidst friends and colleagues all enjoying the hospitality of Professor Nicolaides. As always, the congress was a huge success and left all who were involved looking forward to next year's congress which is expected to be in Chania, Crete and it will be announced in the coming few months on the **FMF Website**.



Professor Nicolaides



Panel Discussion

Highlights from the 7th Phoenix Fetal Cardiology Symposium Held in Phoenix, Arizona 3 - 7 May 2016. By Joan Mastrobattista, MD

It was an honor and a privilege to attend and speak at the **7th Phoenix Fetal Cardiology Symposium**, a conference whose participants included maternal-fetal medicine specialists, pediatric cardiologists, neonatologists and sonographers that highlighted advances in imaging, diagnosis and management of fetal cardiac abnormalities in May 2016. The atmosphere was relaxed but exciting to be in one location with so many leaders in the field of fetal cardiology who were extremely accessible and most interested in sharing their areas of expertise. This meeting also hosted the "First Honorary Abraham M. Rudolph Lectureship", which led the audience through the history of Pediatric Cardiology.

The preconvention program highlighted the sequential segmental analysis of the heart and reviewed atrial, ventricular and atrioventricular septal defects and fetal echocardiography exam preparation. The afternoon concluded with a review of conotruncal anomalies and a hands-on teaching session and a pathology specimen review (normal & abnormal fetal cardiac specimens were on display for hands-on learning). General session topics included the gamut from embryology to pathologic specimens, knobology, Doppler, neurodevelopment, hands-on 3D sonography, extracardiac, TTTS, arrhythmias, major congenital cardiac lesions and fetal therapy. Several references were made to the scientific statement from the American Heart Association "**Diagnosis and Treatment of Fetal Cardiac Disease**". Dr. Mary Donofrio, lead author, gave cutting-edge talks on fetal predictors of neurodevelopmental outcome, Tetralogy of Fallot, and introduced the new "**Fetal Heart Society**". Goals of the Fetal Heart Society are to advance the field of fetal cardiovascular care and science through collaborative research, education and mentorship. Their webpage lists key articles and associated organizations, and they welcome new members. Some additional take-home messages addressed the importance of becoming familiar with the half-life of antiarrhythmic drugs as some are quite prolonged (amiodorone - 54 days). An antiarrhythmic can stop an arrhythmia but can also cause one. In addition, the sonologist needs to become familiar with the ultrasound machine package controls. Another practical pearl is that the optimal angle of insonation for Doppler is 0 degrees (complete alignment). Other key points on Doppler optimization may be reviewed by accessing the ISUOG Practice Guideline on the "**Use of Doppler Ultrasonography in Obstetrics**". Finally, for image optimization when carrying out a fetal echocardiogram, the sonologist should adjust PRF (pulse repetition frequency), wall motion filter and sweep speed.

Overall, this conference was well worth the time away from patient care and family; speakers were leaders in their field, very approachable and topics were cutting edge. Stay tuned for information on next year's symposium.



Phoenix



Drs. Copel & Donofrio


CFAFC Recommends: Fundamental and Advanced Fetal Imaging

With the rising role of fetal MRI in fetal imaging, there is mounting evidence as to its complementary role to ultrasound and a need for better instruction as to when to use it, its additive value and image interpretation. To that end, Kline-Fath, Bulas and Bahado-Singh have released **"Fundamental and Advanced Fetal Imaging"** (Wolters Kluwer 2015), a comprehensive textbook which addresses these 2 modalities in every imaginable aspect of normal as well as abnormal fetal assessment.

There are 55 distinguished contributors who have written detailed reviews with magnificent images all compiled into the text's 23 chapters. The text is divided into two parts. Part 1 addresses normal fetal anatomy as well as the role of the various modalities in assessing fetal well-being: 3D ultrasound, Doppler, MRI and the various biochemical markers. It includes a 51 page chapter on the assessment of cardiac function. Part 2 of the text addresses fetal malformations and here, several chapters are further subdivided into sections. For instance, for the fetal CNS, there are 3 sections: supratentorial anomalies, infections and posterior fossa anomalies.

What distinguishes this text is that it is replete with MRI images of both normal and abnormal fetuses. In addition, the contributions of MFM specialists, pediatric cardiologists, radiologists as well as geneticists provide the reader with a wealth of information from key members of the medical team, each with their unique approach and input.

The text also provides the reader with an "Inkling" code in order to download it on smartphones/tablets for easy immediate access. CFAFC highly recommends this text to all who are involved in fetal imaging.



THIS AND THAT

SMFM Abstract Submission



Abstract submission is now open for the **SMFM's Pregnancy Meeting** to be held in Las Vegas January 23-28, 2017. As always, this meeting shall provide cutting edge research on all aspects of maternal as well as fetal medicine, and shall include comprehensive pre-congress courses, the "late breaking research" session in addition to the plenary sessions and poster presentations. For details, visit the **SMFM Website**.

AIUM Abstract Submission



Abstract submission is now open through September 28 for the upcoming **Annual Convention of the AIUM** to be held in Orlando from March 25-29, 2017. The convention promises to bring local as well as international experts who shall present the latest on all aspects pertaining to the use of ultrasound in over 19 different tracks, representing the AIUM's various communities and special interest groups. Details at the **AIUM Website**.

ISUOG Pre-Congress Courses



The upcoming **ISUOG World Congress** promises to be a landmark congress this year with the highest number of submitted abstracts and an exciting program planned. Attendees are encouraged to check out the pre-congress courses in order to register early for these comprehensive sessions. This year the pre-congress courses will be held on Saturday 24 September 2016 and shall cover Oncology, Emerging Technologies in Prenatal Diagnosis as well as Basic Training. Details at **ISUOG Website**.

Upcoming UCLA Symposium



The **6th Annual UCLA Fetal Echocardiography Symposium** will be held in Los Angeles on October 15, 2016. Building on the success of the previous years, the symposium brings together leaders in fetal echocardiography who shall share their experience with the attendees via an intense program of theoretical as well as hands on sessions. For further details, contact the course chair, Dr. Sklansky, at msklansky@mednet.ucla.edu.

CFAFC News



It has been an intense few months for **CFAFC's** Reem S. Abu-Rustum. The latest CFAFC research appeared in **AJP Reports**. She was invited to participate in the **ISUOG** BT and Outreach Summit in London as a member of its core working group. She was recognized by the **BJOG** as a "top reviewer" for the **5th year in a row**. She was appointed to the **ISUOG** Web Development Task Force. She provided the Fetal Echocardiography lecture to the **AUBMC** Ob/Gyn residents as part of their ultrasound curriculum. She is honored to have participated in all these endeavors...

SANA Medical NGO Turns 5

On 19 May 2016, **SANA** turned 5 and reflects back on 5 amazing years of growing and giving. SANA is ever so grateful to her supporters who have enabled SANA to:



- * Provide complete prenatal care and sonography to over 1400 patients
- * Complete basic sonographic training and provide ISUOG Certification to 10 midwives and nurses
- * Provide ongoing sonographic training, currently at various phases, to physicians, Ob/Gyn residents, midwives and nurses
- * Integrate ultrasound education into the curriculum of the midwifery students at the Lebanese University, Tripoli Branch
- * Participate in several ISUOG Guideline translations into Arabic
- * Carry out research on the role of ultrasound in the Lebanese Outreach and in education
- * Commence live streaming of ISUOG courses to physicians and residents

SANA has acquired a simulator which was made possible by the generosity of the Elmer and Mamdouha Bobst Foundation and facilitated by the support of **SonoSim**. Read about SANA's **trainees' experience**: enabled by the simulator, they have demonstrated significant improvements in their technical skills and are making headway towards fulfilling requirements for ISUOG Certification.

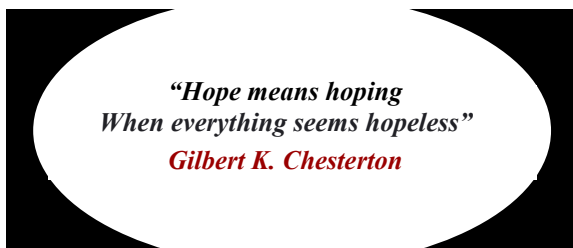
A special art exhibit "Unattainable Dream" is planned on the occasion of SANA's 5th anniversary. The exhibit will feature paintings by Dr. Issam Elias at the University of Balamand, October 18 - 25, 2016. The exhibit was inspired by dear Sana and is dedicated to SANA. Stay tuned to **SANA's Facebook Page**.



Center For Advanced Fetal Care

Najah Center 1st Floor
Aasheer Al Dayeh Street
Tripoli - Lebanon
Cell +96170236648

CF AFC expresses its sincerest appreciation to all of our contributors. For any interesting case reports, comments, suggestions or announcements, please send an e-mail to rar@cfafc.org.



Kindly note that all colored text contains embedded '[clickable](#)' links.

Prenatal Diagnosis of Hydrocolpos. Case by Drs. I. Ghosn, S. Hasbani, H. Abdallah and N. Helou.

We present the case of a 32 year old lady, gravida 1 para 0, who was referred to our hospital at 39 weeks of gestation for a cystic fetal pelvic mass. There was no notable family or medical history, and her pregnancy had been uncomplicated thus far.

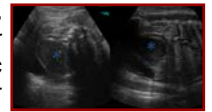


Figure 1

Transabdominal scan showed a female fetus with an echogenic fluid-filled, pear-shaped median pelvic mass measuring 6 x 4 cm. It was situated behind the fetal bladder and extended to the perineum on sagittal imaging (Figure 1 *blue). No other anomalies were noted. For further assessment, a fetal MRI was performed.

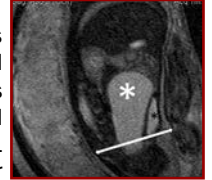


Figure 2

It defined the pelvic lesion which created a mass effect on the posterior wall of the bladder (Figure 2 *black). The lesion extended all the way to the pelvic floor (Figure 2 white double arrow) and showed hypersignal intensity on T2W sequences (Figure 2 *white) as well as hyposignal intensity on T1W sequences. The diagnosis of hydrocolpos was thus established. The patient delivered a liveborn baby girl and upon inspection of the newborn's external genitalia, a bulging imperforate hymen was noted. It was incised and the hydrocolpos was evacuated successfully.

Imperforate hymen is a rare congenital malformation where the hymen obstructs the vaginal introitus leading to hydrocolpos and in more severe cases, to hydrometrocolpos (Adaletli et al 2007). It is rarely diagnosed prenatally (Winderl et al 1995). As in our case, diagnosis by ultrasound was possible in the late third trimester. In such cases, fetal MRI may prove to be of additive value, as it did in our case, where it clearly demonstrated the extension of the lesion below the pelvic floor, providing further evidence in support of the prenatal diagnosis. When these cases are missed prenatally, the hydrocolpos may resolve spontaneously rendering the patient symptom-free. Otherwise, the patient may remain asymptomatic and undiagnosed until puberty.

Upcoming Congresses

COURSE TITLE	DATES	LOCATION	WEBSITE ADDRESS
The International Symposium on the Fetal Brain	Sept 15-16, 2016	Washington, DC	www.cvent.com/events/fetal-brain-conference/event-summary-43642a63631c46f79ce630a219f5b7e8.aspx
Advanced Sonography Symposium in Ob/Gyn	Sept 16-18, 2016	Boston, MA	http://cmeregistration.hms.harvard.edu/events/advanced-sonography-symposium-in-ob-gyn/event-summary-6fdca1e8b9dd4290a4b0ab47d030ea04.aspx
Fetal & Neonatal Physiological Society	Sept 17-20, 2016	Cambridge, UK	https://research.pdn.cam.ac.uk/fnps/
4th World Congress on Ultrasound in Medical Education	Sept 23-25, 2016	Lubbock, TX	www.wcume.org/
26th Annual Congress of ISUOG	Sept 24-28, 2016	Rome, Italy	www.isuog.org/WorldCongress/2016/
Advances in Ultrasound in Obstetrics & Gynecology	Oct 14-15, 2016	Washington, DC	www.edusymp.com/product/brochure/930
6th Annual Fetal Echo Symposium at UCLA	Oct 15, 2016	Los Angeles, CA	www.cme.ucla.edu/courses/event-description?registration_id=124261
7th Annual Fetal Echocardiography: Normal and Abnormal Hearts	Nov 3 -5, 2016	Las Vegas, NV	www.edusymp.com/product/details/890
5th International Fetal Growth Meeting	Nov 17-19, 2016	Toronto, Canada	www.fetalgrowth2016.ca
25th Annual OB-GYN Ultrasound Update for Clinical Practice	Dec 1-4, 2016	Lago Mar, FL	www.cmebyplaza.com/Default3.aspx
Advances in Fetal Medicine	Dec 3-4, 2016	London, UK	https://fetalmedicine.org/courses-and-congress/fmf-advances-course