



Center For Advanced Fetal Care Newsletter

Volume 4 Issue 4
Autumn of 2013
Tripoli - Lebanon

INSIDE THIS ISSUE

CNS...	1
FTS for Anomalies	1
NT & Heart Defects	1
2nd WCUME Highlights	2
23rd ISUOG Congress	2
AIUM Portal for 2013:YOU	2
Sound Judgment Series	3
Upcoming FMF Course	3
Upcoming SMFM	3
New ISPD Newsletter	3
App: Primary Care by IMNG	3
CFAFC News	3
TICS Spotlight	3
Featured Case	4
Upcoming Congresses	4

CNS...

Clarity. Nerve. Scrupulousness. Critical CNS components of our most complicated lateral brain, needed as we journey through and **experience** life, seeking clarity in the haze, in order for us to focus, make wise, bold decisions and provide proper guidance to all who are under our care. With much intrigue and temptations along the way, never-ending challenges and constant additions to our armamentarium of diagnostic tools, we must never lose sight of our mission and goal. We must honor our Hippocratic Oath of "first do no harm" in order to minimize the inherent pain and prevent any inflicted pain. With as much knowledge as there is today, it is impossible to stay abreast with all the newest advances. Sub-specialization, coupled with collaboration amongst colleagues from the various disciplines, becomes the pillar to ensure the best care to our patients and the best education to our students. We thus dedicate this issue to the "CNS", the focus of the \$ 110 million US **BRAIN Initiative** and the recent € 1.2 billion EU-cofounded **Human Brain Project** (HBP). We present to you the latest reports pertaining to the inevitable "bold" role of the first trimester ultrasound scan for the early screening of structural abnormalities and congenital heart disease in the wake of the world-wide spread of non-invasive prenatal testing. We share with you highlights from the 2nd World Congress on Ultrasound in Medical Education which reinforced the revolutionary role that ultrasound has, and shall continue to play, in educating our future generation of health care providers. We present to you highlights from the 23rd World Congress of ISUOG. And with this issue, we feature our final 2013:YOU quarterly spotlight, which is on the newly established AIUM Portal for Ultrasound in Medical Education, an asset to any program wishing to integrate ultrasound into medical education or further expand their program. We recommend the Journal of Ultrasound in Medicine's Sound Judgment Series, with the recent article on the sonographic diagnosis of placenta accreta. And in addition to our usual quarterly features, we present to you a "Spotlight" on the earliest evidence for the prenatal origins of cerebral asymmetry. Together, and with clarity, nerve and scrupulousness, we may ensure a safe outcome for our patients, and a promising future to our future physicians...



Starry Night Over the Rhone
Vincent van Gogh Sept 1888

Editor-in-Chief

Reem S. Abu-Rustum, MD
Center For Advanced Fetal Care
rar@cfafc.org

Editorial Board

Khalil Abi-Nader, MD
LAU and UMC-Rizk Hospital
khalil.abinader@lau.edu.lb

Marcel Achkar, PharmD
Nini Hospital
marcelachkar@yahoo.fr

Georges Beyrouthy, MD
geobey1@hotmail.com

Linda Daou, MD
Hotel Dieu de France
lindadaou@hotmail.com

Assaad Kesrouani, MD
Hotel Dieu de France
kesrouani@doctor.com

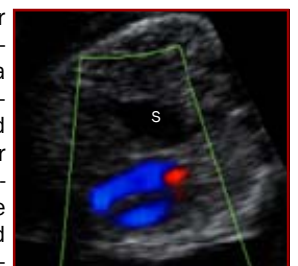Bernard Nasr, MD
Fetal Care Clinic
nasrbernard@hotmail.com

Malek Nassar, MD
Centre de Diagnostic Prenatal
cdp686@gmail.com

Roland Tannous, MD
Tripoli Perinatal Clinic
tpc2020@gmail.com

An Extended Examination Protocol for FT Structural Anomalies

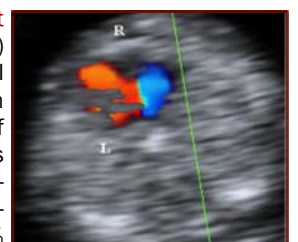
A recent study by Iliescu et al on improving the detection rate of first trimester structural anomalies utilizing an extended examination protocol was recently published (*Ultrasound Obstet Gynecol* 2013; 42: 300-309). The authors carried out a prospective study over a 2 year period on 5472 fetuses presenting for a first trimester scan at 12 to 13+6 weeks in which an anomaly scan was carried out and in addition to that, a cardiac sweep with color Doppler (assessing the 4 chamber view, outflow tracts as well as confluence of aortic and ductal arches) was obtained, and various contingency markers were evaluated. The fetuses were rescanned in the second trimester at 18-22 weeks. The prevalence of lethal and severe malformations in this population was 1.39%. Utilizing an extended examination protocol, the authors were able to detect 40% of all anomalies and 76.3% of all major structural abnormalities and 90% of congenital heart defects. However, the CNS, with the developmental limitations, remained a challenge with a detection rate of 69.5%. Interestingly, 67.1% of all anomalies had a normal NT. The authors conclude that an extended examination protocol is an efficient method to screen a low risk population.



First Trimester Diaphragmatic Hernia

NT and Major Congenital Heart Defects: A Meta-Analysis

A recent meta-analysis by Sotiriades et al was just published (*Ultrasound Obstet Gynecol* 2013; 42: 383-389) addressing the role of the nuchal translucency (NT) in the early diagnosis of congenital heart disease (CHD) in fetuses with a normal karyotype. The authors pooled data from 20 studies including 205232 fetuses in order to establish the sensitivity and specificity of the NT in the early diagnosis of CHD. The pooled sensitivities and specificities from studies in which the NT was measured by sonographers certified by the Fetal Medicine Foundation were higher than those in which the sonographers were not certified. For the certified sonographers, an NT > 95% had a sensitivity of 45.6% and a specificity of 94.7% whereas an NT > 99% had a sensitivity of 21% and a specificity of 99.2% with a pooled likelihood ratio for an NT > 99% of 30.5. Nonetheless there was significant heterogeneity in the results indicating remaining underlying unidentified bias.



NT > 95% in Hypoplastic Left Ventricle

Highlights from the Second World Congress on Ultrasound in Medical Education Held From 27-29 Sept 2013, Columbia SC

It was back to the warm hospitality of the friendly south that over 500 delegates and 100 congress faculty, representing 82 universities from 21 countries from around the world, as well as from global leading institutions, returned to Columbia, South Carolina for the 2nd WCUME. This was a 2013:Year of Ultrasound event and a joint effort carried out by SUSME (Society of Ultrasound in Medical Education) and WINFCOUS, and it was hosted by the University of South Carolina.

The program was a rich intense program with visionary plenary sessions given by the pioneers of the fields on all topics pertaining to the ever expanding role of ultrasound and whether it is in medical education, at the point-of-care-setting or in the outreach setting.

There were over 30 hands-on workshops, and perhaps one of the most impactful was the workshop covering the ultrasound curricula at 6 medical schools in the USA. This workshop addressed the futuristic technologies and methodologies that are currently being utilized: from a digital portfolio for each student at the University of Ohio, to instructional podcasts on iTunes at the University of California, Irvine, to Ultrasound OSCE's at the University of South Carolina, to training Med 4 students as effective educators at George Washington University, to a simulation-enriched program at Texas Tech University and finally, to a special anatomy site at Eastern Virginia Medical School. And another most helpful workshop was "Initiating an Ultrasound Curriculum From A to Z" which covered every single aspect needed for initiating and expanding an ultrasound-integrated curriculum.

There were over 100 original oral and poster abstracts presented at the 2nd WCUME, and interacting with the abstract presenters and hearing the impact that ultrasound has had on their careers was an enlightening experiencing. This was especially true in the cases of the Junior Residents who had attended medical school in which ultrasound was integrated into their curricula. Hearing the positive impact that this distinguishing skill has had on their acceptance into residency programs, and how instrumental their skill is proving to be on the wards where most of their seniors cannot use ultrasound, further reinforced the inevitable need for future integration of ultrasound into all curricula around the globe. In addition, Lebanon was again represented at the 2nd WCUME. The Lebanese experience at the first year medical student level at the University of Balamand, the first such experience in the Middle East, was presented via 2 oral presentations.

And as the 1st WCUME was, the 2nd WCUME, with its rich educational program, and the memorable taste of the arts at the welcome reception at the Columbia Museum of Art, precisely proved to be yet another unforgettable learning experience, another "turning point" in an albeit long journey of seeking clarity in the haze...



With Permission from www.wcume.org



With Permission from www.wcume.org



With Permission from www.wcume.org


Highlights from ISUOG's 23rd Annual Congress Held in Sydney Australia from 6 - 9 October 2013 in Collaboration with ASUM

ISUOG, together with the Australian Society of Ultrasound in Medicine, held its 23rd Annual Congress in Sydney and welcomed 1400 delegates from over 65 countries from around the globe. And as is customary with ISUOG's congresses, this proved to be a highly impactful meeting with several pre-congress workshops covering such topics as "Prenatal Screening and Diagnosis of Aneuploidy", "Endometriosis" as well as "Ultrasound in the O&G Office". In addition, there were several "Meet the Professor" sessions and daily live scan demonstrations. The high calibre of the congress was again evident throughout the presented abstracts, in the oral communication and poster sessions, which can be viewed via ISUOG's OnDemand channel. One highly notable abstract, for which lead author Carolina Nastri won the top abstract award, gained a lot of attention. The abstract entitled "Early pregnancy defines late pregnancy events: Endometrial injury: how a pregnancy event impacts on the likelihood of a successful pregnancy" was presented by co-author Wellington Martins at the ISUOG opening plenaries. In this prospective randomized study on 158 women of whom 77 were randomized to have endometrial scratching, the authors assess the impact of inflicted endometrial injury prior to infertility treatment on successful pregnancy and live birth rates. The rate of pregnancy increased from 29% to 49% and the rate of live births increased from 23% to 42% in women who underwent endometrial scratching. Further larger studies are currently underway to further validate these findings. The ISUOG Outreach Workshop had a new interesting format this year in which abstracts pertaining to experience in the outreach setting were presented. There were a total of 5 main presentations addressing experience from Africa and Australia with discussions following each by the inspiring leaders of ISUOG Outreach. And yet again, the unprecedented Dr. Benoit stunned the audience with his 3D images in which he depicted with unbelievable clarity various challenging fetal conditions and he showed several examples of cases of fetal facial clefts as well as cases of trisomy 21 fetuses. After a memorable meeting, the congress closed awaiting the reopening of ISUOG's 24th Annual Congress in Barcelona, Spain. Next year's congress will be held from 14-17 September 2014 and further details are currently available at the ISUOG Website.



Quarterly Feature 2013:YOU... The Newly Developed AIUM Portal

In his Sound Waves letter to the AIUM Membership, Steven R. Goldstein MD, AIUM President stated: "I believe there is no more important issue facing ultrasound than its incorporation into undergraduate medical schools' curricula"... And with that the AIUM, during 2013: the Year of Ultrasound, together with the AIUM Ultrasound in Medical Education Special Interest Group, chaired by David P. Bahner, MD, RDMS has recently launched the Ultrasound in Medical Education Portal. The portal is instrumental at all stages of initiating and expanding an ultrasound-integrated curriculum. The portal's home page features a schematic of the human body whereby, with rolling the mouse over it, sample sonographic images are generated depicting where ultrasound may be used in the human body. The portal includes live testimonials from medical students, at various levels of their training, sharing the benefits of having ultrasound education integrated into their curricula. There are several most useful features of the portal. The "Tool Kit" provides all the information needed for any program to get started, connect with their leadership, recruit faculty, establish a curriculum, know what equipment to secure and be able to assess the students proficiency. And under the "Medical School" page is a listing of all US Medical Schools, together with various international medical schools, showing their level of ultrasound integration. And under the "Mentor Program" is a listing of mostly US and a few global volunteers with experience in ultrasound willing to serve as mentors to students and help medical schools with their integration. We extend our congratulations to the AIUM and its Ultrasound in Medical Education Special Interest Group for their leadership and vision, and for making available this instrumental resource in order to help clarify the path for the much needed global integration of ultrasound into medical education...



CFAFC's Recommendation: JUM's Sound Judgment Series

A little over 19 months ago, in February 2012, the *Journal of Ultrasound in Medicine* (JUM) launched the "Sound Judgment" series dedicated to providing timely and up-to-date scientific evidence in support of ultrasound's role as the modality of choice for various clinical conditions. This was in parallel with the AIUM's "Ultrasound First" initiative dedicated to providing health care providers with ample scientific evidence in order to have them consider and utilize ultrasound first in various clinical scenarios, where in addition to its availability, it is safe, cost effective and affordable.

To date there have been over 24 sound judgment articles and all are available for free download on the websites of JUM and *Ultrasound First*. Of those 24, six articles are dedicated to various obstetrical and gynecological conditions such as postmenopausal bleeding, endometriosis, adenomyosis, acute pelvic pain, uterine anomalies and abnormal placentation.

In the most recent Sound Judgment article "**Prenatal Diagnosis of Placenta Accreta: Is Sonography All we Need?**", which appeared in the August 2013 issue of JUM, Berkley and Abuhamad present a comprehensive overview of placenta accreta, discuss the typical clinical presentation, diagnosis, the 3 key sonographic findings in the first trimester as well the key 6 sonographic findings in the second and third trimesters. The authors discuss the role of MRI which they argue should be reserved for cases where ultrasound is non-diagnostic, the patient is obese or the placenta is posterior. In addition, the authors provide ample evidence in support of ultrasound as the first line modality in properly trained hands due to its availability, affordability, noninvasiveness and the fact that it is of higher sensitivity when compared to MRI: 86.4% versus 84%.

In summary, the Sound Judgment series is a must-read series for all those who use ultrasound, as it sheds the light on the key sonographic features in the most challenging of clinical scenarios where one may be at a loss and feels the need for cross-sectional imaging. However, with employing "sound judgment" and utilizing the key sonographic signs, clarity is ensured and it is possible to arrive at immediate accurate point-of-care diagnoses at no additional cost, and with minimal invasiveness to the patient ...



www.ultrasoundfirst.org



www.jultrasoundmed.org

THIS AND THAT

Upcoming Nicolaides Course



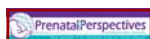
Mark your calendars for another of Professor Nicolaides' most memorable advanced courses to be held in London December 14 and 15. And though the program is not yet available, attendees can rest assured that the 12+ hours packed days shall be a most intense, clinically-impactful experience with world-renowned faculty members. [Online registration](#) is now open.

Upcoming SMFM



The 34th Annual Pregnancy Meeting is planned in New Orleans February 3-8. Pre-congress sessions include: Obstetrics Controversies & Debates, Diabetes & Pregnancy, Clinical Pearls in Fetal Cardiology, Prenatal Genetics in Clinical Practice, Quality Improvement & Patient Safety in MFM, Fetal Monitoring 2014, Management of Previa Birth, Obesity in Pregnancy, Clinical Pearls in Fetal Imaging, Critical Care and Emergency Obstetrics and finally Twins, Triplets and Beyond. Registration commences November 1 and is available online at the [SMFM Annual Meeting Page](#).

ISPD Newsletter



The International Society of Prenatal Diagnosis has launched a quarterly newsletter "*Prenatal Perspectives*" under the editorship of Prof. van Lith, Benn, Schielen and Siljee. This is a most comprehensive newsletter with personal commentaries and reports from around the globe on all issues pertaining to prenatal diagnosis from ethics, to counseling, to cutting-edge research. The editorial board welcomes contributions from colleagues. Submissions/questions may be sent to editors@ispdhome.org.

Recommended App: Primary Care News by IMNG



This new App from the publishers of Ob/Gyn news is available for the iPad and provides free access to over 31 topics such as Obstetrics, Gynecology, Adolescent Medicine, Behavior, Infertility, Breast Cancer to name a few. The app can be personalized to particular areas of interest and provides up-to-date headline news, upcoming conferences as well as expert views...

CFAFC News



This issue of the CFAFC Newsletter marks issue #16 and is the last issue of year 4. CFAFC extends its thank you to our readership for their support and interest in the Newsletter. Since 2010, the number of visitors to the [CFAFC Website](#), from 108 countries, has been steadily growing. It has increased from 884 in 2010, to 1875 in 2011, to 2283 in 2012, and to date in 2013, we have already had over 2248 visitors. The CFAFC Newsletter has remained the most visited/downloaded feature of our website. Our deepest appreciation to you: your support keeps us going...

Hot-Off-The-Press from Trends in Cognitive Sciences

ARTICLE IN PRESS

Spotlight

Cell PRESS

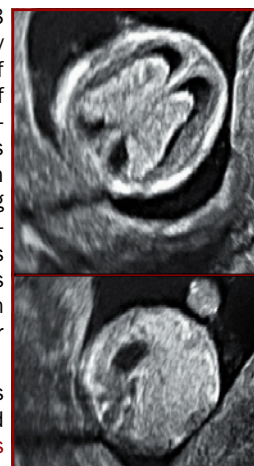
Early signs of brain asymmetry

Michael C. Corballis
School of Psychology, University of Auckland, Private Bag 92019, Auckland, New Zealand

A new study shows a leftward asymmetry of the choroid plexus in two-thirds of first-trimester human fetuses. This is the earliest brain asymmetry so far identified and may be a precursor to other asymmetries, including that of the temporal planum, which is evident from the 31st week of gestation.

in the third and fourth ventricles, and fills the lateral ventricles in the first trimester. The shape of the choroid plexus, the so-called 'butterfly sign', in the lateral ventricles has proven to be one of the most sensitive first-trimester sign of brain abnormalities [4], and it is in this region that the asymmetry was apparent [Figure 1].
There is reason to conjecture that this asymmetry

A recent "Spotlight" (ePub ahead of print 8 Oct 2013) in *Trends in Cognitive Sciences* by Michael Corballis, PhD from the University of Auckland, New Zealand, addresses one of the earliest signs of brain asymmetry identified to date. Professor Corballis discusses the human brains' functional asymmetry with the near universal right handedness among humans, and the left hemisphere's specialization for speech and language. And this asymmetry has given rise to "various notions of fundamental duality pervading human affairs, whether in art, politics, religion, or even business."



In the spotlight, Professor Corballis discusses a recent study from Lebanon just published in the *Journal of Ultrasound in Medicine's* September issue, on the fetal choroid plexus at 11-13 weeks in which there was leftward asymmetry in two thirds of fetuses evaluated. According to Corballis, this is the earliest brain asymmetry identified thus far and may be an underlying precursor to functional asymmetry pending further study and evaluation.

With the key role that the choroid plexus has in the secretion of key chemorepellants, cytokines, growth factors and neuropeptides that serve to repair and protect, and its large size in the first trimester which creates shorter diffusional distances with the thin neuroepithelium to facilitate the delivery of these key peptides, this asymmetry of the choroid plexus in the 11-13 week fetus may underlie the asymmetry of the temporal planum. Corballis thus argues that a lack of asymmetry of the first trimester choroid plexus may be indicative of later functional irregularities and may potentially serve as an early marker for other schizotypy and intrusive hallucinations.



Center For Advanced Fetal Care

Najah Center 1st Floor
Aasheer Al Dayeh Street
Tripoli - Lebanon
Cell +96170236648

CFAFC would like to thank Prof. Michael Corballis, Dr. Bernard Nasr, and ISUOG Secretariat for their contributions. For closure, CFAFC acknowledges the compartmentalized human CNS for ensuring clarity in the haze...



For any interesting case reports, comments, suggestions or announcements to be included in our newsletter, please send an e-mail to rar@cfafc.org.

Prenatal Diagnosis of TRAP by Bernard Nasr, MD

A 32 year old G2 P1001, IVF conception with transfer of 3 embryos, presented for evaluation. Scan at 8 weeks revealed a viable fetus with another adjacent irregular empty sac (Figure 1). Follow-up at 12 weeks revealed monochorionic (MC) twins with one viable fetus, NT of 0.8 mm, and a normal anatomical survey. However there was an adjacent mass with a clear feeding vessel that crossed over the intertwin membrane with no evidence of cardiac activity seen within the mass (Figures 2, 3). As such, the diagnosis of twin reversed arterial perfusion (TRAP) sequence was made. On follow-up at 14 weeks, there seemed to be spontaneous occlusion of the feeding vessel and the only remnant was a small sac-like structure with no flow to it demonstrable on color Doppler (Figure 4).

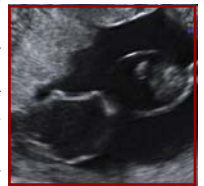

Figure 1

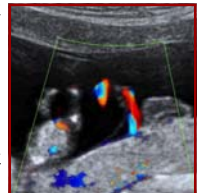


Figure 2

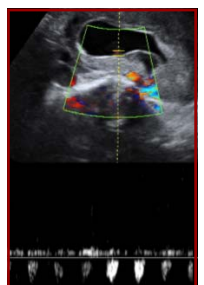

Figure 3

Acardiac twinning, or TRAP, complicates 1% of MC twin gestations. It is usually a result of circulatory failure that affects one of the twins, occurs between 8 and 12 weeks, and leads to specific angioarchitecture characterized by arterio-arterial and veno-venous inter-twin anastomosis that result in an abnormal embryological twin mass (acardiac twin). Oftentimes, the acardiac twin has severe malformations and is more akin morphologically to a tumor than to a fetus.

The optimal management of TRAP remains unclear. Expectant management may lead to heart failure in the pump twin. As such, interruption of the vascularization to the acardiac twin is an option whether by ultrasound-guided fetal cord ligation or compression, bipolar coagulation, laser coagulation, transection with harmonic ultrasound scalpel, thermocoagulation or radiofrequency ablation. Though these modalities are comparable in terms of fetal survival, the main concern in choosing the ideal approach is prematurity which has been reported to be significantly less for radiofrequency, 23%, versus the other modalities, 58% (p=0.003).

As our case illustrates, early diagnosis of TRAP sequence is possible and allows follow-up and early intervention if necessary. In our case there was spontaneous occlusion of the feeding vessel. The pregnancy is still ongoing and is at 27 weeks with a fetus that has a normal anatomical survey and appropriate fetal growth.

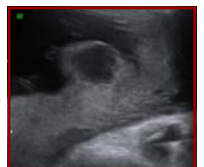

Figure 4

Upcoming Congresses

COURSE TITLE	DATES	LOCATION	WEBSITE ADDRESS
16th Mid Atlantic Symposium in Ob/Gyn Ultrasound	November 8-9, 2013	Norfolk, VA	www.evms.edu/education/cme/the_16th_annual_midatlantic_ultrasound_symposium_in_obstetrics_gynecology/
Annual Congress of the Lebanese Society of Obstetrics & Gynecology	November 14-16, 2013	Beirut, Lebanon	www.isog.2013.com
4th International Symposium in Fetal Medicine & Gynecology	November 21-23, 2013	Cordoba, Argentina	www.diagnus.com/areamedica/simposio
7eme Congres de Medecine Foetale	November 25-27, 2013	Montpellier, France	www.congres-medecinefoetale.fr/Programme_a22.html
22nd Annual Ob/Gyn Update for Clinical Practice	December 5-8, 2013	Ft Lauderdale, FL	www.cmebyplaza.com/Registrants/GoHo13/About.aspx
Fetal Medicine Foundation's Advanced Ultrasound Course	December 14-15, 2013	London, UK	www.fetalmedicine.com/fmf/courses-congress/03-fmf-courses/
Maternal - Fetal Imaging 2014	January 24-26, 2014	San Antonio, TX	www.cvent.com/events/maternal-fetal-imaging-2014
34th Annual Meeting of the Society of Maternal Fetal Medicine	February 3-8, 2014	New Orleans, LA	www.smfm.org/Annual%20Meeting%20Page.cfm
37th Annual Advanced Ultrasound Seminar in Ob/Gyn	February 14-16, 2014	Lake Buena Vista, FL	www.aium.org/cme/events.aspx
3rd International Congress on Cardiac Problems in Pregnancy	February 20-23, 2014	Venice, Italy	www.cppcongress.com