



Center for Advanced Fetal Care
Tripoli - Lebanon

Viability Scan

Date: 14 February 2010

Patient: XxXxXx XxXxXx

Date of Birth: 01 January 1992

Deir Aamar

Lebanon

Tel. private: 06000000

Tel. mobile: 71000000

Hospital No: 54244

Present Pregnancy

Dates	Last period: 07/12/2009
Cycle	regular - LMP sure
Conception	spontaneous
Pregnancy test	positive
EDD by dates	13/09/2010
EDD by scan	13/09/2010
Maternal blood group	O, Rhesus positive
Weight	63.0 kg
Height	156.0 cm
Body mass index	25.9
Cigarettes	no
Alcohol	no

Obstetric History

Gravida 1 Para 0

Family History

Patient: uncomplicated family history

Partner: uncomplicated family history

consanguinity no

Examination

Date 25/01/2010

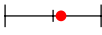
Time 09:43

Department CFAFC

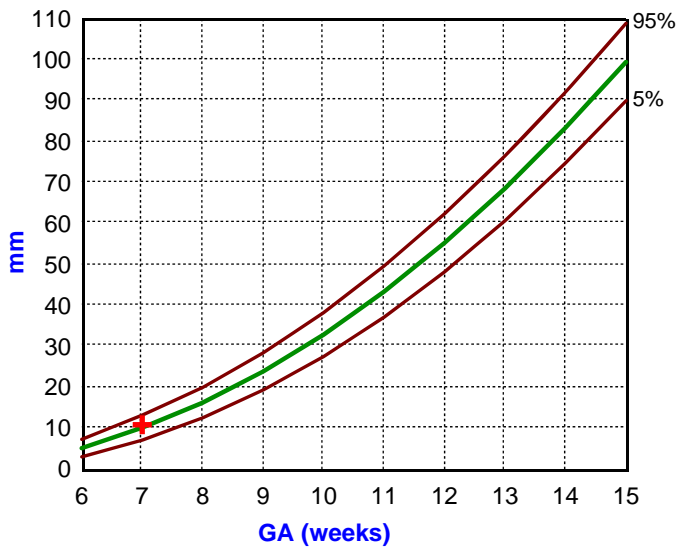
Ultrasound

Operator Reem S. Abu-Rustum, MD, FACOG
US system GE Voluson 730 Expert BT05
transabdominal, 3D
View good
Gestational age 7 weeks + 0 days

Assessment of early pregnancy

Urinary pregnancy test positive
Pregnancy site within the intrauterine cavity
Morphology gestational sac
Yolk sac seen
Embryo present
CRL 10.9 mm 
Heartbeat present
Fetal heart rate 133 bpm
Final diagnosis and management summary viable intrauterine pregnancy

Crown-rump length



Robinson HP, Fleming JEE: British Journal of Obstetrics and Gynaecology; Sep 1975;Vol 82;pp 702-710

Comments

Viable IUP at 7w0d. Will plan the first trimester screen using NT, NB and TR at 11w6d to 13w6d.

Reem S. Abu-Rustum, MD, FACOG